



## Summary Feedback

### ST1 – ST4 Teaching Programme 2024

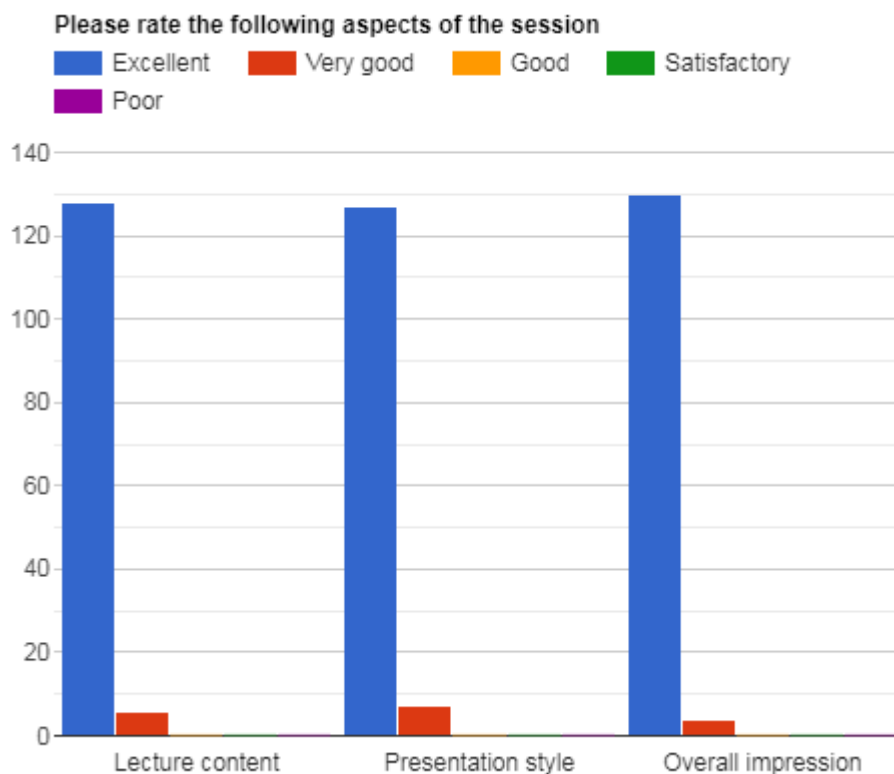
#### DKT FRCR 2B Practice Viva (Session 47)

#### DKT Spotlight Series - Mastering CT in Acute Abdomen (Part 2) (25<sup>th</sup> January 2024)

Delivered By:  
(Sami Khan)

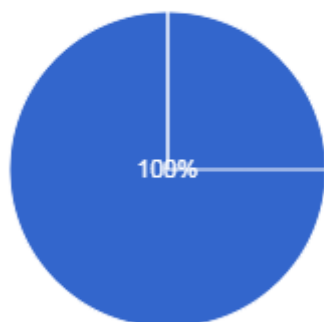
#### Summary Points:

- ST1-ST4 teaching programme 2023 – FRCR 2B Practice Viva Session 47: 2 hours teaching time
- Total Attendees: 360 from 35 Countries (Algeria, Australia, Canada, China, Czech Republic, Dominica, Egypt, Hong Kong, India, Indonesia, Iraq, Ireland, Jordan, Kenya, Kuwait, Malaysia, Myanmar, Namibia, Nepal, Nigeria, Norway, Oman, Pakistan, Qatar, Saudi Arabia, South Africa, Sri Lanka, Sudan, Swaziland, Türkiye, UAE, UK, Yemen, Zambia, Zimbabwe).
- Total feedback received from 134 participants



Did you find it useful  
134 responses

● Yes  
● No



## Testimonials

- Wow! Such a wide selection of pathology in the acute abdomen! Some of these cases and manifestations I have never seen before! Dr Khan has simplified it in such an easy way! Learnt so much. Thank you (UK).
- Awesome teacher, so dedicated to teaching and to the radiology practice, it's just amazing and so much inspiring too (Saudi Arabia).
- Very excellent. Just when you think you know it all then Dr.Khan shows you more than you would imagine. He makes radiology very fun indeed (Kenya).
- Great teaching cases. No one teaches like Dr. Khan. Many thanks (Iraq).
- Fantastic session with great clear discussion, including different cases of acute abdomen. It definitely turned the theoretical radiological knowledge into a real life radiological signs (Egypt).
- Really interesting cases, well showed and straight to the point, the fact that candidates interpreted first was excellent so we don't make the same mistakes (Algeria).
- Excellent as always. I am a great fan of your teaching methods (UK).
- Excellent cases. Excellent teaching. Dr Khan is always the best at delivering lectures and teaching. Sir you are legend. Very useful (Pakistan).
- Excellent! I have truly gained alot by following these lectures, amazing how much one can learn by attending these lectures, thank you DKT (Kenya).
- Dr Khan always have a great variety of cases starting from the anatomy to the management for each case (Jordan).
- Keep up the excellent work! We all appreciate your time to educate us (UK).
- The way of teaching is unbelievable and the effort put in the session is enormous. Thank you so much sir, You definitely make a difference (Egypt).
- Always educative and interactive (UK).
- Really very good lecture and very nice cases . I enjoyed every second of the lecture (UK).

## DKT FRCR 2B Practice Viva (Session 47) DKT Spotlight Series - Mastering CT in Acute Abdomen (Part 2)

- Excellent resource for learning radiology (UK).
- It was the best lecture (Pakistan).
- All the cases were excellent and helpful for exam and day to day reporting (Pakistan).
- Superb session, well done (India).
- I liked the case selection and discussion (UAE).
- Excellent session (UAE).
- Clear explanation (India).
- I liked the key points to describe everything (India).
- Everything was useful (Pakistan).
- Always amazing (UK).
- Dr Khan, we have come a long way while watching your lectures. They help us in daily reporting. Thank you for the help (Pakistan).
- Very good session and cases. Exam oriented (UK).
- Excellent. Something for everyone at every level (Pakistan).
- Fantastic lecture (Malaysia).
- Excellent teaching session (Algeria).
- Wonderful (Egypt).
- I liked the variation of the cases (Egypt).
- Teaching and the presentation was useful (UK).
- I liked the cases approach (Egypt).
- Descriptions after the cases was useful (UK).
- The cases and the post-case explanation was useful (Norway).
- Excellent explanation of abdominal emergencies and great cases (Pakistan).
- Helpful in daily reporting (Pakistan).
- Uncommon presentation of common pathology was useful (Nigeria).
- Got some ideas on describing cases (Sri Lanka).
- Very helpful (UAE).
- I liked the presentation of different types of hernia which i haven't seen practically (Pakistan).
- Interesting cases (UK).
- All cases were excellent. Really very good cases (Pakistan).
- I liked the content and delivery (UK).
- Very interesting cases and a wide variety of them, excellent way of presentation (UK).
- All cases are interesting (Egypt).
- Viva style is great. Fabulous cases (UK).
- All cases were great (Egypt).
- Very good cases and explanations, thank you (UK).
- I liked the basics of CT especially how to trace the bowel (Pakistan).
- Numerous interesting cases are demonstrated (Malaysia).
- Everything is important (UK).
- Amazing session (UK).
- Interesting cases and revision slides (Algeria).
- Perfect coverage (Egypt).
- It was perfect (UAE).
- Amazing collection of cases (Egypt).

## DKT FRCR 2B Practice Viva (Session 47) DKT Spotlight Series - Mastering CT in Acute Abdomen (Part 2)

- I liked the way Dr.Khan Sir conduct the session (UAE).
- Beautiful cases (Qatar).
- I liked the case discussion (UK).
- Challenging exam style cases (UK).
- How to correlate between radiology and pathology was useful (Oman).
- Nice cases and nice dealing with their (Egypt).
- Variety of classical cases and the sequential presentation (Sudan).
- Lot of interesting cases shared (Nigeria).
- I liked the Dr Khan's kind and patient behavior (Pakistan).
- Very interesting cases with many learning points (UK).
- Nice diagrams (Sudan).
- Incredible cases with excellent explanation (UK).
- Everything as usual! (Kenya).
- I liked the cases and focuses explanation/teaching points (UK).
- Excellent cases, excellent teaching points, diagrams and images (Pakistan).
- Excellent cases and teaching (Kenya).
- Interesting cases that are tricky to diagnose (Egypt).
- Informative cases and topics (UK).
- Pointing the pathological area from the image, discussion with theories background were useful (Myanmar).
- The cases were excellent (India).
- It keeps me up to date (UK).
- Great knowledge (Pakistan).
- Best (Pakistan).
- Perfect (Pakistan).
- Awesome (UAE).
- Perfect lecture (Egypt).
- Good (Pakistan).
- Wow (Pakistan).
- Excellent (UAE).
- Very informative (UAE).
- Excellent session (Pakistan).
- Useful for revision (Norway).
- Excellent thank you (Egypt).
- Very nice and good cases with alot of challenges (UAE)
- Excellent lecture (Pakistan).
- Great (UK).
- Fantastic (UK).
- Great lectures (Egypt).
- Thank you (UAE).
- Thank you so much for your efforts (Qatar).
- Excellent (UK).
- Great efforts. Thank you (Sudan).
- Excellent, will try to attend many more (UK).

# DKT FRCR 2B Practice Viva (Session 47) DKT Spotlight Series - Mastering CT in Acute Abdomen (Part 2)

- Par excellence (Pakistan).
- Quick overview of the most important cases (Sudan).
- Excellent work (Kenya).
- Excellent (Pakistan).
- Awesome (Indonesia).
- Excellent (Myanmar).
- Very good (UK).
- I like it very much (Pakistan).
- Very good (UAE).

Recording... | You are viewing Dr. Khan's Teaching's screen | View Options | 01:26:00 | View

### The pubic tubercle: a CT landmark in groin hernia

Delabrousse, E., Denué, PO., Aubry, S. *et al.* The pubic tubercle: a CT landmark in groin hernia. *Abdom Imaging* 32, 803–806 (2007)

Unmute | Start Video | Security | Participants | Chat | Share Screen | Summary | AI Companion | Pause/Stop Recording | Show Captions | Reactions | Apps | Whiteboards | Notes | Leave

# DKT FRCR 2B Practice Viva (Session 47) DKT Spotlight Series - Mastering CT in Acute Abdomen (Part 2)

Recording Paused

You are viewing Dr. Khan's Teaching's screen

DR. KHAN'S TEACHING  
The 8-10 Day of FRCR 2B Exam

DKT FRCR 2B PRACTICE VIVA SESSION 47  
**DKT SPOTLIGHT SERIES**  
**MASTERING CT**  
**IN ACUTE ABDOMEN**  
**(PART 2)**

25 JANUARY, 2024  
**18:30-20:30 GMT**

**DR. SAMI KHAN**  
CONSULTANT RADIOLOGIST  
BASILDON UNIVERSITY HOSPITAL, UK

For Registration:  
[www.drkhansteaching.com](http://www.drkhansteaching.com)

25-01-2024

205 Participants

Recording Paused

Recording...

You are viewing Dr. Khan's Teaching's screen

## Inferior epigastric Artery

Case courtesy of Craig Hacking, Radiopaedia.org, rID: 81909

354 Participants

Recording...

=====**XX**=====**XX**=====